

FIRST CASES OF SEVERE FLACCID PARALYSIS ASSOCIATED WITH ENTEROVIRUS D68 INFECTION IN SPAIN, 2015–2016

*María Cabrerizo, PhD,**

Juan Pablo García-Iñiguez, MD, PhD,†

Francina Munell, MD, PhD,‡ Alfonso Amado, MD,§

Paula Madurga-Revilla, MD,†

Carlos Rodrigo, MD, PhD,‡¶ Sonia Pérez, PhD,||

*Ana Martínez-Sapiña, MD,** Andrés Antón, PhD,††*

Gerardo Suárez, MD,§ Nuria Rabella, MD, PhD,‡‡

*Victor del Campo, MD,§§ Almudena Otero,**

and Josefa Masa-Calles, MD, PhD¶¶

Abstract: Enterovirus D68 was known to be the cause of mild to severe respiratory infections, but in the last few years, it has also been associated with myelitis and paralysis. This report describes the first Enterovirus D68 detections in acute flaccid paralysis cases occurring between December 2015 and March 2016 in Spain.

Key Words: enterovirus infection, pediatric, severe neurologic diseases, surveillance

Accepted for publication January 26, 2017.

From the *Spanish National Poliovirus Laboratory, National Centre for Microbiology, Institute of Health “Carlos III”, Madrid, Spain; †Department of Pediatrics and **Department of Microbiology, Miguel Servet Hospital, Zaragoza, Spain; ‡Department of Pediatrics, Vall d’Hebron University Hospital and Autònoma University, Barcelona, Spain; §Department of Pediatrics and §§Department of Preventive Medicine, University Hospital of Vigo (Alvaro Cunqueiro Hospital), Vigo, Pontevedra, Spain; ¶University Hospital Germans Trias i Pujol School of Medicine, Barcelona, Spain; ||Department of Microbiology, University Hospital of Vigo (Meixoeiro Hospital), Vigo, Spain; ††Department of Microbiology, Vall d’Hebron University Hospital, Vall d’Hebron Research Institute, Barcelona, Spain; ‡‡Department of Microbiology, Santa Creu i Sant Pau Hospital, Barcelona, Spain; and ¶¶National Centre for Epidemiology, Institute of Health “Carlos III” and CIBERESP, Madrid, Spain.

The authors have no funding or conflicts of interest to disclose.

Address for correspondence: María Cabrerizo, PhD, Enterovirus Unit, National Centre for Microbiology, Instituto de Salud Carlos III, Ctra. Majadahonda-Pozuelo km 2, Madrid, Spain. E-mail: mcabrerizo@isciii.es.

Supplemental digital content is available for this article. Direct URL citations appear in the printed text and are provided in the HTML and PDF versions of this article on the journal’s website (www.pidj.com).

Copyright © 2017 Wolters Kluwer Health, Inc. All rights reserved.

DOI: 10.1097/INF.0000000000001668

Enterovirus D68 (EV-D68) belongs to species D within *Enterovirus* genus of the *Picornaviridae* family. Since it was first identified in 1962, EV-D68 had been considered as a low circulation EV type associated with mild respiratory infections.¹ However, a significant increase of severe respiratory illnesses caused by EV-D68 was reported in the United States during late summer and fall of 2014.² Furthermore, the notification of subsequent neurologic complications in several cases characterized by acute flaccid paralysis (AFP) revealed the existence of a possible association between EV-D68 infection and severe neurologic diseases.³

The first reported cases of AFP associated with EV-D68 infection in Spain occurred between December 2015 and March 2016. The cases were clinically identified as a polio-like illness and subsequently reported to the National AFP Surveillance System, implemented in Spain since 1998 within the National Plan for Polio Eradication. All AFP cases diagnosed in children younger than 15 years of age in any Spanish region must be reported and investigated.⁴

THE STUDY

A 4-year-old boy was admitted to the Miguel Servet Hospital (Zaragoza) on December 3, 2015 (day 1). He presented fever, vomiting, general weakness and paresis in right arm. Two days earlier, the boy had been taken to his pediatrician with sore throat, and he had been diagnosed with acute pharyngo-tonsillitis. Blood, cerebrospinal fluid (CSF; days 1 and 6), respiratory samples (days 8 and 9) and stools (days 8 and 12) were collected. Bacteriologic investigations in blood and CSF yielded negative results. Blood and CSF analysis revealed leukocytosis with neutrophilia, CSF pleocytosis and high protein concentrations, consistent with meningoencephalitis. Intravenous antimicrobial therapy was initiated. On December 4 (day 2), he presented clinical worsening, with paralysis of all extremities, dysphagia and respiratory distress, and was transferred to the pediatric intensive care unit to start ventilatory support. Cerebral magnetic resonance imaging (MRI) showed gadolinium enhancement of the rhombencephalon and bulbomedullary. The stool samples collected were sent to the Spanish National Poliovirus Laboratory for poliovirus investigation following mandatory WHO protocols based on viral culture of the stool samples in RD and L20B cells.⁵ Viral cultures were negative. However, EV was detected in both fecal specimens by reverse transcriptase polymerase chain reaction (RT-PCR) in the 5′-noncoding region of the viral genome. Sequencing of the PCR products suggested EV-D68, which was confirmed by a specific EV-D68 RT-PCR assay in the 3′-VP1 region of the viral genome. Designed EV-D68 PCR was performed in the same conditions of a previously published RT-PCR for EV-A, B and C,⁶ changing the oligonucleotides in the second round of PCR (5′-GTACCMACCTGGTGCTCTTAC and 3′-CTGATTGCCARTCCACATAG). PCR analysis of 2 CSF samples revealed no intrathecal EV, but the 2 nasopharyngeal specimens also resulted EV-D68 positive. Seven months later, the boy remained hospitalized with paresis, needing mechanical ventilation while sleeping. He recovered partial mobility of the lower extremities and of his left arm and was slowly regaining trunk control.

On February 4, 2016, a 2-year-old girl was referred to her pediatrician because of acute bronchitis and low-grade fever. On February 10 (day 1), evident worsening of respiratory distress was detected, and the patient was hospitalized in the pediatric intensive care unit of Vall d’Hebron University Hospital (Barcelona). One day after admission, she developed distal weakness in the upper limbs, an altered level of consciousness and progressive respiratory acidosis requiring endotracheal intubation. The limb weakness progressed within hours to complete flaccid paralysis. MRI images revealed brainstem and extensive spine lesions, mainly involving pontine tegmentum, medulla oblongata and the cervical anterior horn region (Fig. 1A and B). Intravenous antimicrobial therapy was initiated. On February 19, the AFP case was reported, and 2 stool samples were sent to the subnational polio laboratory in Hospital de la Santa Creu i Sant Pau (Barcelona) for polio investigation. Blood, CSF (day 1), nasopharyngeal specimens (days 1 and 2) and stool samples (days 2 and 4) were collected. Bacteriologic investigations in blood culture yielded negative results. Blood analysis showed $23,610 \times 10^6$ leukocytes/mm³, 58% of neutrophils and 37% of lymphocytes. EV was detected in the 2 respiratory samples and the 2 stool specimens by PCR-based methods. Genotyping performed in the National Poliovirus Laboratory confirmed EV-D68 as the causative agent. Viral cultures of stools were negative. The patient received intravenous methylprednisolone and immunoglobulins followed by plasmapheresis. Five months after the onset of the illness, the patient remained hospitalized and had recovered facial movement and expression, and she was able to move the right arm, fingers and toes, to articulate words and to swallow fluids and pureed food.

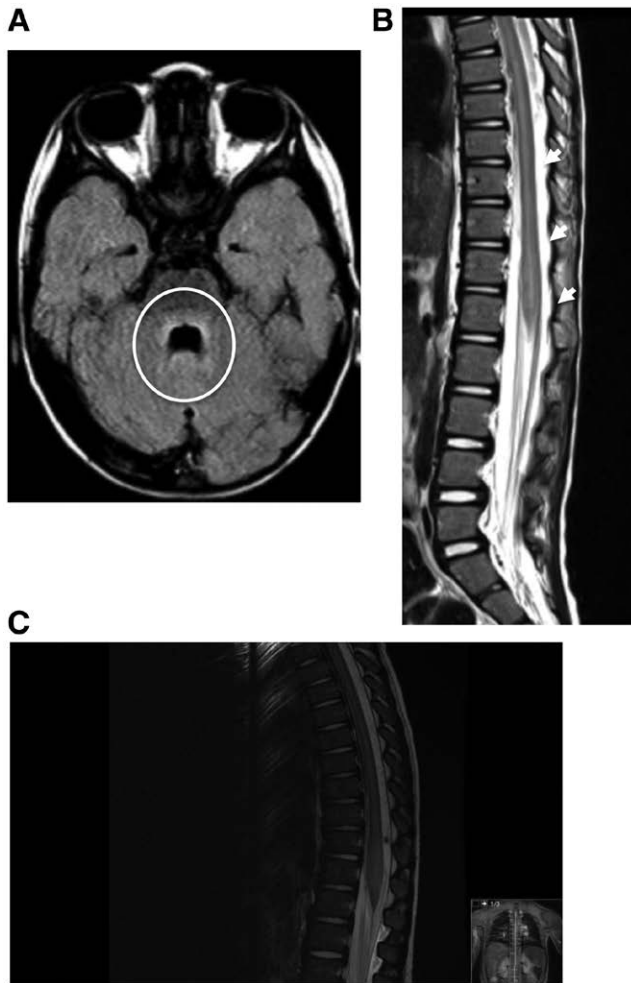


FIGURE 1. A, Rhomboencephalitis and (B) myelitis in cerebral and spinal magnetic resonance imaging (courtesy of the Neuroradiology Unit, Department of Pediatric Radiology, Vall d'Hebron University Hospital). C, Medullary magnetic resonance imaging showing a long segment of myelitis from C1-CS to the medullary cone.

The third case was a 20-month-old boy admitted to the Alvaro Cunqueiro Hospital (Vigo, Pontevedra) on March 22, 2016 (day 1), with general muscle weakness (reduced ambulation), generalized pain during movement, hypoactive periods alternating with irritability and hyporeflexia. He had presented with fever and respiratory symptoms in the previous days. He was a twin and was born premature (31 week of gestation). Blood, CSF, nasopharyngeal aspirate (day 1) and stool (day 10) samples were collected. CSF biochemistry showed 142 leukocytes (75% mononuclear). Intravenous antimicrobial treatment was initiated. Brain MRI showed leptomeningitis, with brain and spinal cord involvement predominantly in medullary. Long segment of myelitis from about C1-C2 to the medullary cone, slightly expansionary in medullary cone, predominant central involvement and enhancement with postcontrast, all suggested acute flaccid myelitis as the clinical criteria defined by Centers for Disease Control and Prevention (Fig. 1C). He received corticosteroid and immunoglobulin treatments. Clinical case evolution was flaccid paresis with areflexia and generalized

muscular hypotonia. Bacteriologic investigations in blood and CSF yielded negative results. EV-D68 was detected by RT-PCR in nasopharyngeal aspirate and the stool samples. Viral cultures of stool specimen were negative. Two months after the onset of clinical manifestations, he presented stable seating position, with adequate mobility of both upper limbs. Lower limb paresis associated with hyporeflexia persisted.

The 3 patients were previously healthy and fully vaccinated according to the Spanish vaccination program, including 4 doses of inactivate poliovirus vaccine. They had not travelled recently outside Spain.

EV-D68 SEQUENCE ANALYSIS

Phylogenetic investigation of the 9 EV-D68 3'-VP1 sequences obtained in the 3 cases indicated that they belonged to clade B as have almost all sequences circulating since the 2014 epidemic.⁷ However, Spanish strains from 2015 belonged to subclade B2, while those from the 2 cases occurring in 2016 were clustered in the new subclade B3, a grouping with strains from China and Taiwan (2014)⁷ (Fig., Supplemental Digital Content 1, <http://links.lww.com/INF/C753>). The sequences obtained in this study have been deposited in GenBank under accession numbers KX949556-KX949564.

DISCUSSION

Polioviruses are known to be the main cause of AFP. When the incidence of poliomyelitis decreased as a result of the Global Polio Eradication Initiative, new cases of AFP because of other emerging non-polio EV types (as EV-71) were described.⁸ Until mid-2014, EV-D68 was exclusively associated with mild respiratory diseases, but during the 2014 EV-D68 outbreaks throughout North America, severe respiratory complications, including fatal outcomes, were reported. Furthermore, cases of AFP were described in which only EV-D68 could be detected.³ Subsequent to US reports, cases of severe paralysis or myelitis associated with EV-D68 infection were identified in France, Norway, Australia and Great Britain.^{9–13}

In this report, EV-D68 was detected in fecal and respiratory samples of 3 children with AFP or acute flaccid myelitis, additional cases that support the putative association between EV-D68 infection and neurologic disease. Clinically, the cases described here are similar to others reported,^{3,9–13} respiratory illness preceding development of neurologic symptoms characterized by acute onset of limb weakness, with MRI showing a spinal cord injury. As in most of the cases described previously, EV-D68 was detected in respiratory samples but not in CSF. However, nondetection of EV-D68 in CSF does not necessarily rule out its implication in neurologic disease, as poliovirus and EV-A71 are frequently not recovered in CSF of AFP cases. Although sporadically, EV-D68 has been detected in CSF from other published cases with fever, fatal meningo-myeloencephalitis or AFP, supporting the idea that EV-D68 is able to cause neurologic diseases.^{12,14} Furthermore, a recent report suggests that intercellular adhesion molecule 5, a protein expressed on the surface of telencephalic neurons, could be a functional entry receptor for EV-D68.¹⁵

On the other hand, partial sequencing of viral VP1 gene from Spanish cases showed similar strains to those detected in non-AFP cases from Spain and other European, Asian and American countries. An increase in the number of APF cases associated with EV-D68 may not be because of an increase of virulence of a specific strain; however, basic pathologic studies are needed to confirm the neurotropism of EV-D68.

Although RD cells are permissive for EV-D68 infection, RD cultures inoculated with stool samples from all cases were negative. However, cells were incubated at 36°C, as recommended by the WHO's Polio Manual,⁵ and it is known that EV-D68 shares biologic features with rhinoviruses and prefers lower culture temperatures.¹⁵

The EV-D68-associated AFP cases reported were identified through the National AFP Surveillance System, implemented as a measure in the Global Polio Eradication Initiative, where all paralysis cases diagnosed in children must be reported and investigated for poliovirus detection.⁴ From October 2015 to March 2016, 14 AFP cases were studied in Spain. In 5 of them (36%), non-polio EV were detected in feces, 1 coxsackievirus-A6, 1 coxsackievirus-A22 and 3 EV-D68. Unfortunately, since Spain was declared "polio-free" in 2002, not all AFP cases that occurred in the country have been reported for poliovirus investigation. First EV-D68 detection in AFP cases in Spain highlights the need to identify all AFP cases and to perform an appropriate screening not only for polio but also for emerging non-polio enterovirus in AFP and other neurologic pathologies. To keep an active EV surveillance to identify and monitor circulating types is increasingly important to ensure that polioviruses are not reintroduced into those countries that have been polio-free for years and to identify the etiologic agent of new diseases or outbreaks.

ACKNOWLEDGMENTS

We thank I. Bustillo, H. del Pozo and P. Higuera for their technical assistance and G. Trallero who has been responsible of the National Poliovirus Laboratory for 27 years. We thank I. Delgado, A. Sánchez and E. Vázquez from Neuroradiology Unit, Department of Pediatric Radiology (Vall d'Hebron University Hospital). We also sincerely thank all technical staff from Microbiology Departments and medical staff from Pediatrics Departments. All procedures performed in studies involving human participants were in accordance with the ethical standards of the 1964 Helsinki Declaration. Collection of clinical and microbiologic data was approved by the institutional ethics board of each hospital, and informed consent was obtained from the 3 patients' family.

REFERENCES

- Centers for Disease Control and Prevention (CDC). Clusters of acute respiratory illness associated with human enterovirus 68: Asia, Europe, and United States, 2008 to 2010. *MMWR Morb Mortal Wkly Rep*. 2011;60:1301–1304.
- Messacar K, Abzug MJ, Dominguez SR. 2014 outbreak of enterovirus D68 in North America. *J Med Virol*. 2016;88:739–745.
- Greninger AL, Naccache SN, Messacar K, et al. A novel outbreak enterovirus D68 strain associated with acute flaccid myelitis cases in the USA (2012–14): a retrospective cohort study. *Lancet Infect Dis*. 2015;15:671–682.
- Ministry of Health [Ministerio de Sanidad, Servicios Sociales e Igualdad]. Action Plan in Spain for Polio Eradication, 2016. [Plan de acción en España para la erradicación de la poliomielitis] February 2016. http://www.isciii.es/ISCIII/es/contenidos/fd-servicios-cientifico-tecnicos/fd-vigilancias-alertas/fd-enfermedades/fd-enfermedades-prevenibles-vacunacion/pdf_2016/Plan_Eradicacion_Poliomielitis_2016.pdf
- WHO Polio Laboratory Manual, 2004: An alternative test algorithm for poliovirus isolation and characterization. http://apps.who.int/immunization_monitoring/Supplement_polio_lab_manual.pdf?ua=1
- Cabrerizo M, Echevarria JE, González I, et al. Molecular epidemiological study of HEV-B enteroviruses involved in the increase in meningitis cases occurred in Spain during 2006. *J Med Virol*. 2008;80:1018–1024.
- Gong YN, Yang SL, Shih SR, et al. Molecular evolution and the global reemergence of enterovirus D68 by genome-wide analysis. *Medicine (Baltimore)*. 2016;95:e4416.
- Solomon T, Lewthwaite P, Perera D, et al. Virology, epidemiology, pathogenesis, and control of enterovirus 71. *Lancet Infect Dis*. 2010;10:778–790.
- Lang M, Mirand A, Savy N, et al. Acute flaccid paralysis following enterovirus D68 associated pneumonia. *Euro Surveill*. 2014;19(449):pii 20952.
- Pfeiffer HC, Bragstad K, Skram MK, et al. Two cases of acute severe flaccid myelitis associated with enterovirus D68 infection in children, Norway, autumn 2014. *Euro Surveill*. 2015;20:21062.
- Sherwood MD, Gantt S, Connolly M, et al. Acute flaccid paralysis in a child infected with enterovirus D68: A case report. *BCM J*. 2014;56:495–498.
- Levy A, Roberts J, Lang J, et al. Enterovirus D68 disease and molecular epidemiology in Australia. *J Clin Virol*. 2015;69:117–121.
- Williams CJ, Thomas RH, Pickersgill TP, et al. Cluster of atypical adult Guillain-Barré syndrome temporally associated with neurological illness due to EV-D68 in children, South Wales, UK, October 2015 to January 2016. *Euro Surveill*. 2016;21(4):pii 30119.
- Kreuter JD, Barnes A, McCarthy JE, et al. A fatal central nervous system enterovirus 68 infection. *Arch Pathol Lab Med*. 2011;135:793–796.
- Wei W, Guo H, Chang J, et al. ICAM-5/Telencephalin is a functional entry receptor for Enterovirus D68. *Cell Host Microbe*. 2016;20:631–641.

PALPEBRAL ANTHRAX

Adil Bozpolat, MD,* Didem Atici, MD,*
Nazan Ulgen Tekerek, MD,† and Duran Arslan, MD‡

Abstract: A 13-year-old male patient presented with a complaint of swelling of the left eye starting 3 days ago. Bullous lesion and purulent discharge were present on his left eyelids. *Bacillus anthracis* was shown in culture and diagnosis was confirmed. Oculocutaneous anthrax is a rare condition, but the diagnosis should be considered in patients with a painless necrotizing ulcer.

Accepted for publication January 31, 2017.

From the *Department of Pediatrics, †Division of Pediatric Intensive Care Unit, Department of Pediatrics, and ‡Division of Pediatric Gastroenterology, Department of Pediatrics, Faculty of Medicine, Erciyes University, Kayseri, Turkey.

The authors have no funding or conflicts of interest to disclose.

Address for correspondence: Adil Bozpolat, MD, Department of Pediatrics, Faculty of Medicine, Erciyes University, 38039, Talas, Kayseri, Turkey. E-mail: adilbozpolat@gmail.com.

Copyright © 2017 Wolters Kluwer Health, Inc. All rights reserved.

DOI: 10.1097/INF.0000000000001674

Anthrax is a zoonotic disease caused by *Bacillus anthracis*, an aerobic, spore-forming and Gram-positive bacterium. Anthrax is commonly seen among farmers, butchers, veterinarians, shepherds and farm workers. Humans may be affected as a result of exposure to an infected animal or animal product. There are 3 forms of the disease: cutaneous, inhalational and gastrointestinal.¹ The cutaneous form is the most common with a prevalence of 95% and is usually observed on the head, neck and upper extremities.² Cutaneous anthrax is diagnosed from the rapid development of a painless ulcer surrounded by edema. The diagnosis is confirmed by a stained smear of the lesion or isolation of *B. anthracis* from a culture of the infected ulcer or blood.³

Herein, we present the case of an adolescent male with palpebral anthrax that was initially considered as orbital cellulitis or infiltrative lipoma.

CASE REPORT

A 13-year-old male presented with a complaint of swelling of the left eye that had started 3 days previously and was admitted to the emergency department. The patient had no history of any trauma or insect bites. On examination, fever and swelling on the neck spreading to the left half of the face were present. The lesion was painless. A bullous lesion and purulent discharge were present on his left eyelid. There was no other finding on the examination. The patient's body temperature was 40°C. The white blood cell count and acute